



Atlantoaxial fixation: Overview of all techniques

Praveen V. Mummaneni, Regis W. Haid¹

Department of Neurosurgery, Emory University, Crawford Long Hospital, ¹Atlanta Brain and Spine Care, Atlanta, GA, USA

Over the past century, steady advances have been made in fixing an unstable atlantoaxial complex. Current options for fixation of the atlantoaxial complex include posterior clamps, posterior wiring techniques, C1-C2 transarticular screw fixation, posterior C1 lateral mass screw with C2 pars or pedicle screw fixation, and anterior transoral C1 lateral mass to C2 vertebral body fixation.

Key words: Cervical fusion, C1 screws, transarticular

Introduction

Attempts at surgical stabilization of C1 and C2 from a posterior approach date to 1910, when Mixter and Osgood described using heavy silk thread to wire the spinous processes of C1 and C2 together.^[1]

The use of posterior cervical wiring of the lamina of C1 and C2 dates to 1939 in a report by Gallie.^[2] Brooks and Jenkins offered an alternative method of posterior C1-C2 laminar wiring in 1978.^[3] Dickman and Sonntag, et al further modified the posterior wiring technique in 1991.^[4] We will further explore each of these techniques in this review article.

In the 1980's interlaminar clamps^[5] were popularized as an alternative method of posterior C1-C2 fixation.

Posterior screw fixation utilizing C1-C2 transarticular screws and C1 lateral mass screws with C2 pars screws were the final two alternative methods of posterior C1-C2 fixation. The C1 lateral mass screw with C2 pedicle screw construct was initially created with plates and screws by Goel et al in the 1980's.^[6,7] The method has recently gained popularity and a variety of instrumentation is now available for application with this technique (26).

Transoral instrumentation has also been described for stabilization of unstable craniovertebral region, but has received only limited support.

We will discuss the indications and further elucidate the instrumentation options for posterior C1/C2 fixation.

Indications for Posterior C1-C2 Stabilization

Trauma is among the most frequent indications for posterior C1-C2 stabilization. Traumatic injuries that are amendable to posterior C1-C2 fixation include certain subsets of Type II and Type III odontoid fractures.

Although most Type II odontoid fractures can be treated either with immobilization or with anterior odontoid screw fixation,^[9] there are several subsets of this fracture pattern which are not amendable to these treatment measures. These include Type II odontoid fractures associated with fractures of the atlantoaxial joint, Type II odontoid fractures with oblique fractures in the frontal plane that preclude odontoid screw placement, Type II odontoid fractures with significant displacement which may not heal in immobilization (and are too displaced to place an odontoid screw), Type II odontoid fractures with an associated Jefferson fracture, and Type II odontoid fractures with a ruptured transverse ligament.^[9]

In addition, patients with a very large thoracic kyphosis or a very large barrel chest preclude the appropriate angle for anterior odontoid screw placement, and must be treated with a posterior C1 and C2 stabilization procedure.^[9]

Even when there is a Type II odontoid fracture that might heal with immobilization, there are certain cases where immobilization is not practical. Elderly patients in particular do not heal well with immobilization. They have a higher rate of nonunion due to osteoporosis and have increased respiratory morbidity when placed in halo vests.^[8]

In addition, all patients initially treated with immobilization who develop a pseudoarthrosis are not good candidates for subsequent attempts at anterior odontoid screw fixation because of the pseudoarthrotic material occupying the fracture line which prevents contact of the decorticated fracture surfaces.^[9]

For patients who have failed immobilization and are no longer

P. V. Mummaneni

Departments of Neurosurgery and Orthopedic Surgery, Emory University Spine Center, 59 Executive Park South, Suite 3000, Atlanta, GA - 30329, USA, E-mail: vmum@aol.com



good candidates for anterior odontoid screw fixation, C1 and C2 fixation is the only remaining treatment option.

Type III odontoid fractures with atlantoaxial joint fracture combinations and Type III odontoid fractures with associated Jefferson fracture are also unstable and are often best treated with a posterior C1 and C2 stabilization procedure.^[9]

Congenital malformations of C2 (i.e. os odontoideum and odontoid agenesis), degenerative diseases, inflammatory diseases, tumors, and infections can also result in instability of the atlantoaxial complex. Specifically, rheumatoid arthritis can often result in atlantoaxial subluxation or superior migration of the odontoid into the foramen magnum (with compression of the brainstem and upper cervical spinal cord) necessitating a posterior occipitocervical decompression and fusion (with or without transoral resection of the odontoid).

Post-surgical instability relating to C1 and C2 laminectomies with or without removal of adjoining facets is another indication for posterior C1-C2 fixation. We have performed posterior lateral approaches to remove retro-odontoid degenerative masses and also to remove tumors within the spinal canal that inherently destabilize the C1-C2 complex and require posterior C1-C2 fixation.

Patients may also have ligamentous laxity and have resultant C1 and C2 instability. Ligamentous instability of C1/2 is identified with measurements of the atlanto-dental interval on flexion and extension views. Normally this interval should not exceed 2 to 4 mm.^[10,11] When the atlanto-dental exceeds 5 mm in non-rheumatoid patients and when it exceeds 8 mm in rheumatoid patients, there is instability of the C1-C2 complex and posterior C1/2 fixation is indicated.^[12,13,14,15]

Furthermore, atlanto-axial rotatory dislocations are also an indication for C1 and C2 fixation. This problem can be treated via a posterior reduction and fusion approach or via an anterior transoral reduction and C1-C2 fixation.

Methods of posterior C1-C2 Fixation

Posterior C1-C2 fusion with interlaminar clamps

Posterior interlaminar clamps can be used if the C1-C2 lamina are intact. The technique cannot be used if there are significant degenerative changes or if osteoporosis of the posterior elements of C1 and C2 present. In addition, in cases where there is a Jefferson's fracture or a Hangman's fracture this technique cannot be used.

The clamps are used by placing hooks on the superior surface of the C1 lamina and hooks on the inferior surface of the C2 lamina. The hooks are tightened and preferably a bone graft is placed between the two lamina before the laminar clamps are tightened (Figure 1).

Biomechanically, posterior laminar clamps have excellent stability with flexion and extension maneuvers. However, in rotational motion the clamps are not as effective as other techniques involving posterior screws or wires.^[16]

If the posterior clamp construct loosens before bony fusion is achieved, then further surgical intervention will be required.

Consequently, patients are placed in a hard cervical collar or a halo following posterior clamp fusion.

Posterior wiring techniques

The posterior wiring techniques, like the posterior clamping technique, require an intact posterior arch of C1 and C2. They cannot be utilized if there are fractures of the C1 or C2 posterior elements (including Hangman's or Jefferson's fracture), or if posterior decompression of the C1-C2 complex is required, or if there is significant osteoporosis.

Unlike the interlaminar clamping techniques, the posterior wiring techniques require sublaminar passage of a cable and have the potential for injury to the dura or spinal cord during this maneuver.

When we perform posterior wiring techniques, we prefer to use Atlas double braided titanium cables (Medtronic Sofamor Danek, Memphis, TN) because they are more flexible than steel wire and have less chance of causing dural or neural injury.

Gallie fusion

Gallie first described posterior C1-C2 sublaminar wire fixation in 1939 with the use of steel wire.^[17] In the Gallie technique, a single autograft harvested from the iliac crest is notched inferiorly and placed over the C2 spinous process and leaned against the posterior arch of C1. The graft is held in place by a sublaminar wire that passes beneath the arch of C1 and then wraps around the spinous process of C2. Passage of the sublaminar wire under the lamina of C2 is avoided in order to decrease the risk of neural or dural injury.

The Gallie fusion offers good stability in flexion and extension. However, like interlaminar clamping it offers very poor stabilization and rotational maneuvers. Consequently, the rate of nonunion

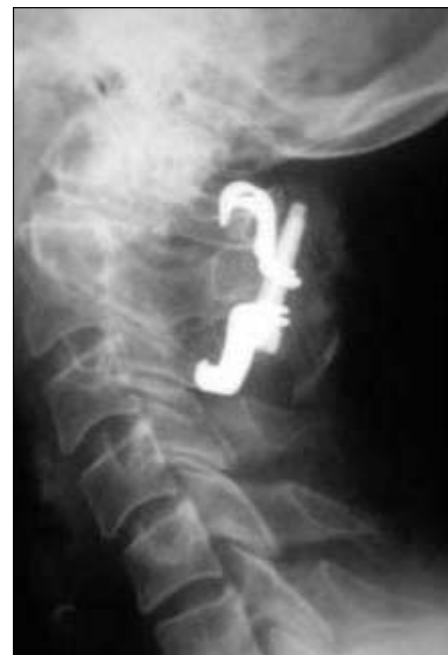

Figure 1: Lateral X-ray of posterior cervical clamp fixation from C1-3

with the Gallie fusion has been reported to be as high as 25%.^[18]

Brooks-Jenkins fusion

In the Brooks-Jenkins fusion technique, unlike the Gallie fusion technique, two separate iliac crest autografts are placed between C1 and C2. Each autologous iliac crest graft is beveled superiorly and inferiorly and wedged in between the C1 and C2 lamina on each side of the midline. One sublaminar cable is then passed on each side of the midline under both the C1 and C2 arches and wrapped around each bone graft respectively. The cables are then tightened around the grafts and secured and crimped in place.

The Brooks-Jenkins fusion technique provides more rotational stability than does the Gallie technique.^[19] The Brooks-Jenkins technique has similar stability in flexion and extension as does the Gallie fusion technique.^[20] The rate of fusion after this technique has been reported to be as high as 93% and is improved by the use of halo immobilization.^[4]

The disadvantages of the Brooks-Jenkins fusion technique include the need for passage of bilateral sublaminar cables beneath both C1 and C2. This entails a higher potential rate of neurological or dural injury than does the single cable passage under the posterior C1 arch for the Gallie technique.^[19]

Sonntag posterior C1-C2 technique

The Gallie technique was modified by Volker Sonntag in the early 1990s. Sonntag's modified technique improves the rotational stability of the Gallie fusion technique while avoiding the bilateral sublaminar C1-C2 cable passage of the Brooks-Jenkins technique.

In the Sonntag technique, a sublaminar cable is passed under the posterior C1 arch from inferior to superior. Next a notched iliac crest is placed in between the spinous process of C2 and wedged underneath the posterior arch of C1 (Figure 2) (unlike the Gallie technique where the bone graft is notched over the spinous process of C2 and simply leaned onto the posterior arch of C1). Both the superior aspect of the C2 spinous process and the inferior arch of C1 are decorticated before graft placement.

The cable is then looped over the iliac crest autograft and placed

into a notch created on the inferior aspect of the C2 spinous process. The cable is then tightened and crimped.

In patients treated with a wiring procedure only, Sonntag recommends the use of a halo to immobilize patients for three months after surgery and the use of a rigid cervical collar for an additional one to two months after that. With this kind of immobilization he has demonstrated a 97% fusion rate with the technique.^[4]

C1-2 transarticular screw technique

In 1979, Magerl and Jeanneret described transarticular screw fixation for the treatment of odontoid fractures. Over the past decade, the senior author (RWH) has used the C1-C2 transarticular screw fixation technique in approximately 100 patients to treat not only C1/2 trauma but also C1/2 inflammatory disease, infection, tumor, congenital anomalies, and acquired (post-surgical) deformities.^[21,22]

One advantage of the C1-2 transarticular screw technique is the complete obliteration of rotational motion of the atlantoaxial joint. However, the disadvantages of this technique are the steep learning curve and the potential for serious complications including errant screw placement leading to spinal cord injury, hypoglossal nerve injury, or vertebral artery laceration.

To avoid complications we routinely perform pre-operative CT scanning of the cervical spine (often with three-dimensional remodeling sequences on a Stealth station (Medtronic Sofamor Danek, Memphis, TN) to identify an anomalous vertebral artery course (Figure 3), destruction of bone at the intended site of screw fixation, or an unacceptably small C2 pars. In addition, we recommend and routinely use pre-operative MRI scanning in order to assess the degree of neural compression and the integrity of the transverse atlantal ligament prior to performing this procedure.

In order to minimize the risk of vertebral artery injury with transarticular facet screw placement, we only place the screw if the preoperative CT confirms the normal anatomic position of the vessel.^[23,24,25] In cases with aberrant unilateral vessel position, we

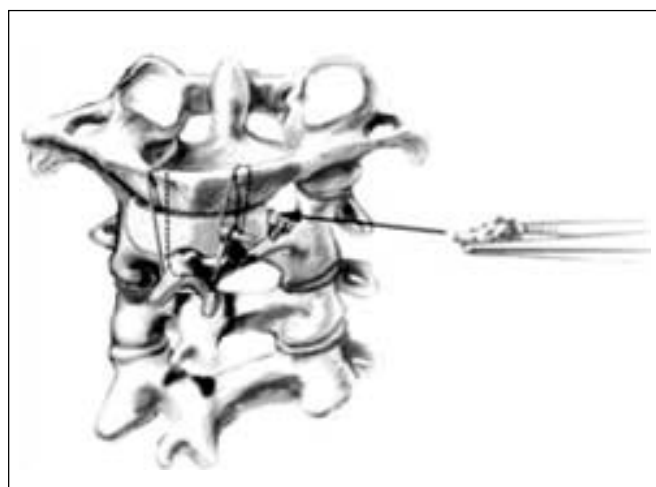


Figure 2: Artist's illustration of Sonntag wire fusion. Additional morsellized autograft may be placed to promote fusion (arrow)

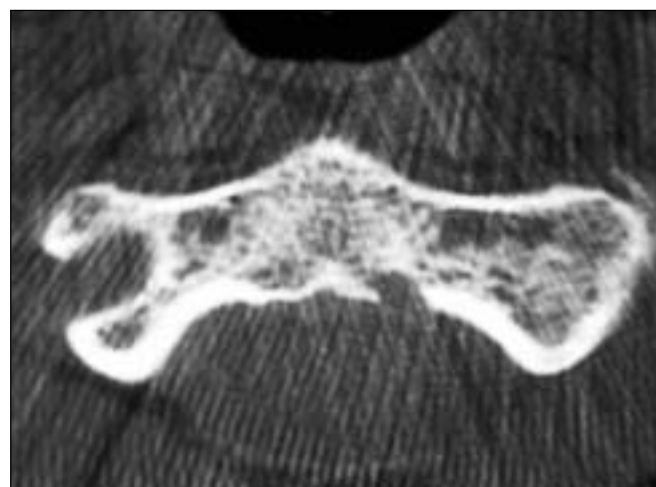


Figure 3: Axial CT scan of C2 revealing aberrant vertebral artery in the intended path of a right C1-2 transarticular screw

place the screw only on the normal side. In case of a vertebral artery injury during screw placement, our preference is to place the screw to tamponade the bleeding. The contralateral screw should not be attempted in this setting in order to avoid the risk of bilateral vertebral artery injury. The patient should be taken to angiography to assess the injury which has occurred and to potentially sacrifice the injured vessel angiographically.

To perform the C1-2 transarticular screw technique, we position the patient prone in a Mayfield head holder (OMI, Inc., Cincinnati, Ohio). We leave the neck in a neutral position and flex the head on the neck in a “military tuck” position (Figure 4A). This affords posterior translation and reduction of the C1-C2 complex allowing the surgeon access to the desired C1-2 trajectory. The patient is prepared and draped to expose from the suboccipital to the mid-thoracic area. Before making a skin incision, we use lateral fluoroscopy we determine the planned entrance site on the skin for the screw trajectory (usually the paramidline area near the T1 spinous process) in order to ensure that enough of the thoracic spine is prepped into the surgical field. We create a separate midline incision to expose the posterior elements of C1-C3.

Next we identify and palpate the bony limits of the C2 lateral mass. The superior and medial aspect of the C2 pars are exposed and palpated with a Penfield dissector. Using the Penfield 4 dissector, the C2 nerve is undermined with gentle sweeping movements in a rostral direction. The Penfield 4 dissector is then passed medially and superiorly over the pars and pedicle of C2 to determine the angle for the screw. There is typically a robust epidural venous plexus on the medial aspect of the pars of C2 which can be controlled by bipolar cautery. We do not dissect on the lateral portion of the pars of C2, as this is not necessary and can increase the risk of bleeding from the paravertebral venous plexus.

In patients with significant C1-C2 subluxation, a reduction of C1 onto C2 must be performed before the screw path can be drilled. The reduction can be accomplished by simple manipulation of the Mayfield head holder, or it can be accomplished by first creating a posterior interspinous tension band with a Sonntag interspinous construct.

With fluoroscopic guidance or with intraoperative neuronavigation with a Stealth station, the proper trajectory is confirmed by placing the drill or similar instrument adjacent to the neck outside of the incision. This trajectory should cross the C1-C2 facet joint and at the anterior arch of the atlas. We usually find that the percutaneous entrance site for the drill lies approximately 2cm lateral to the T1 spinous process (Figure 4B) (and this is why we prepare and drape the upper thoracic spine into the surgical field). We create stab incisions approximately 1cm from the midline bilaterally. We place a guide tube with an obturator through the stab incision site and into the open surgical site at C1-C3. The tip of the guide tube is docked at the C2 entry site. The C2 entry site is identified by locating the inferior medial angle of the C2-C3 facet joint. The entry site is approximately 3-4 mm rostral and 3-4 mm lateral to this point (i.e., from the inferior medial facet joint of C2-3 “go up 3 mm and out 3 mm”).

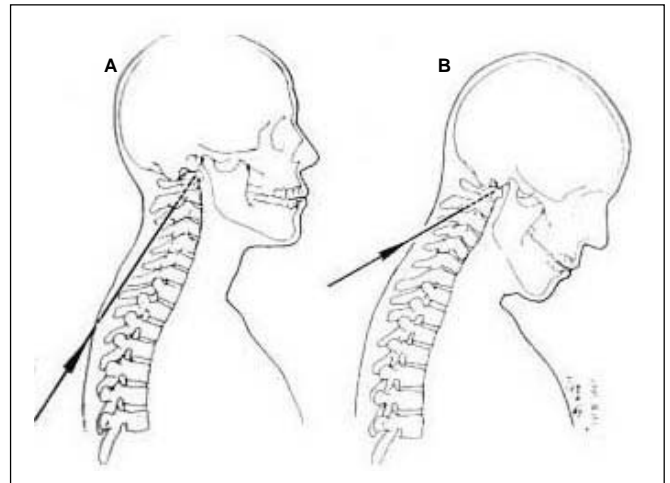


Figure 4: (A) Trajectory for a C1-2 transarticular screw if the patient is positioned without capital flexion of the head on the neck. (B) Trajectory for a C1-2 transarticular screw for a patient positioned with capital flexion of the head on the neck (military tuck position)

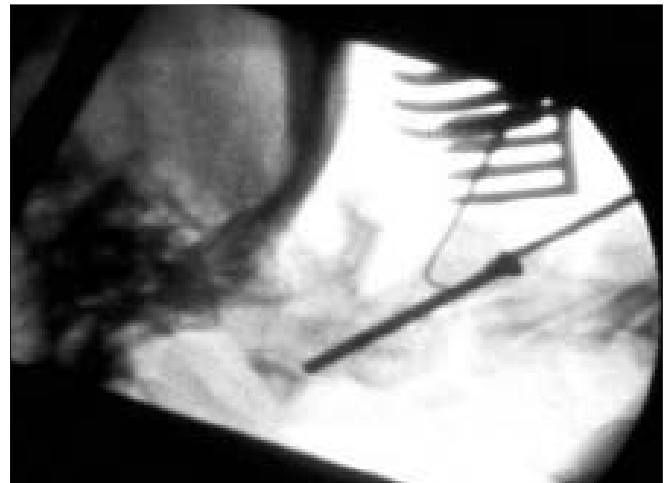


Figure 5: Lateral X-ray of a C1-2 transarticular screw placed over a K-wire

With a high speed drill the cortical bone is pierced to mark a K-wire entry site. The K-wire trajectory is typically 15 degrees medial with the superior angle visualized by fluoroscopy. The K-wire is directed down the C2 pars and pedicle complex and across the C1-C2 joint, aiming at the anterior tubercle of C1. The tip of the K-wire is advanced to a point 3-4 mm posterior to the anterior C1 tubercle (to avoid penetration of the wire into the retropharyngeal area).

While the K-wire is drilled, subtle changes may be perceived in resistance as the K-wire subsequently traverses the 4 cortical surfaces along its path into the C1 lateral mass. The cortical surfaces include the posterior C2 entry point, the superior articular surface of C2, the inferior articular surface of C1, and the anterior cortex of C1 ring.

After the K-wire is placed, a cannulated drill bit is passed over the K-wire and drilled to the same target point. Care must be taken to avoid advancing the K-wire further as the drilling is performed. We typically have an assistant hold the K-wire with a

needle driver as the drill bit is advanced in order to avoid advancing the K-wire beyond the anterior arch of C1 and into the soft tissues of the neck.

The pilot hole is then tapped over the K-wire through the C1-C2 facet joint and into the lateral mass of C1. Subsequently, a fully threaded 3.5 mm or 4 mm cortical screw is placed over the K-wire (Figure 5). The necessary screw length can be measured directly from the drill or from the K-wire inserted. The screw is usually 1-3 mm shorter than the actual measured length since some degree of compression of the C1-2 joint occurs with screw placement. (We typically use screws 34-44 mm in length). An oversized screw may breach the anterior cortical margin and injure the pharyngeal soft tissue. On the other hand, a screw that is too short may compromise purchase.

This same technique is repeated on the opposite side as well. If not already performed, we usually supplement transarticular screw fixation with a Somtag posterior interspinous wiring procedure for added stability.^[21,22,26]

We typically mobilize patients in a hard cervical collar for three months after performing the procedure. We prefer to perform the C1-2 transarticular fixation with either Axis screws or UCSS screws (Medtronic Sofamor Danek, Memphis, TN). More recently, we have incorporated a C1/2 transarticular screw into a multi-level cervical construct using the VERTEX polyaxial screw-rod system (Medtronic Sofamor Danek, Memphis, TN).

Goel's C1 lateral mass screw with C2 pars or pedicle screw fixation

The technique of segmental atlantoaxial fixation and fusion using C1 lateral mass screw and C2 pedicle screw and plates was pioneered by Prof Goel et al.^[6] The authors achieved 100% fusion with minimal rate of complications.^[7] The authors advocate bilateral sacrifice of C2 ganglia in order to prepare the atlantoaxial facet joints for arthrodesis.

Goel et al have highlighted the advantage of their method over other constructs.^[7] One of the advantages of the C1 lateral mass in combination with C2 screw technique is that anatomic alignment of the C1-C2 complex is not necessary prior to instrumentation. In addition, this technique can still be utilized in cases where there is an aberrant vertebral artery. The plates act as tension-band, providing stability in flexion/extension and hence a midline procedure by Gallie's fusion or Brooks fusion is not necessary. The procedure is technically demanding and precise and an exact three-dimensional understanding of the anatomy of the region and of the vertebral artery is mandatory. Large venous plexuses in the lateral gutter need to be handled appropriately. Goel et al have reported that sacrifice of the C2 ganglion provides a wide exposure to the region for the conduct of the surgery and does not lead to any significant neurological symptom. Biomechanical testing has shown that C1 lateral mass screw with C2 pars screw construct allows an average of 0.6 degrees more motion than does a C1-2 transarticular screw.^[29]

Recently several authors including us have modified the

technique and use polyaxial screws and top loading rods and do not sacrifice the C2 ganglia.^[26,27]

Surgical technique

The patient is positioned prone using a Mayfield head holder (OMI, Inc, Cincinnati, OH). The neck is kept neutral and the head is placed in the military tuck position. The arms are tucked at the sides. The shoulders are retracted caudally using tape. A midline incision is made extending from the suboccipital area to the spinous process of C3. The C2-C3 facet joints are exposed and the dorsal arch of C1 is exposed laterally exposing the vertebral artery in the vertebral groove on the superior aspect of the C1 arch (sulcus arteriosis). The C2 nerve root is identified and is either sacrificed or mobilized inferiorly. Bipolar cautery and haemostatic agents such as gel foam are used to control bleeding from the venous plexus surrounding the C2 nerve root and also surrounding the vertebral artery. The lateral mass of C1 inferior to the C1 arch is exposed after the C2 nerve root has been sacrificed or mobilized inferiorly. The medial wall of the C1 lateral mass is identified using the forward angle curette to palpate the medial limit of screw placement. The medial aspect of the transverse foramen at C1 and C2 can also be identified and serve as a lateral limit for screw placement.

The entry point for the C1 lateral mass screw is identified at the centre of the C1 lateral mass. Another suggested entry point by Goel et al^[30] is at the junction point of the midpoint of the C1 lateral mass midpoint and the inferior aspect of the C1 arch (Figure 6). It should be noted that the vertebral artery often runs in a sulcus on the superolateral aspect of the C1 arch and care should be taken to avoid drilling in this area (Figure 7).

Using fluoroscopy, a 3 mm drill bit and guide are used to drill a hole with 10-15 degrees medial angulation to penetrate the anterior cortex of C1. On lateral fluoroscopic imaging the drill is aimed towards the anterior tubercle of C1 so that the drill penetrates the ventral cortex of the lateral mass midway between the superior and inferior facets of C1. The hole is tapped and subsequently, a

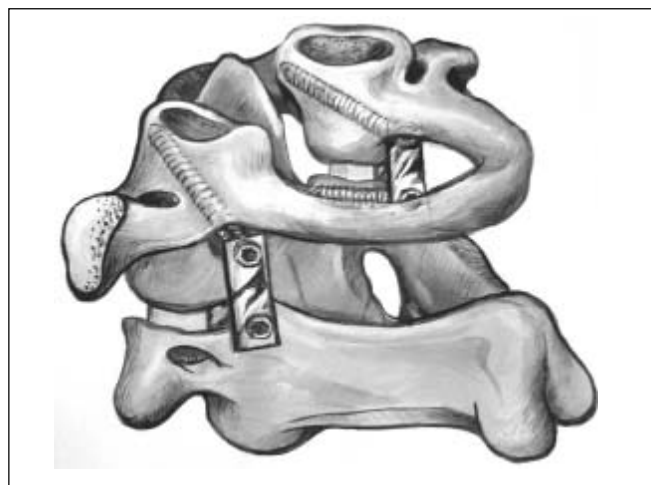


Figure 6: Artist's illustration of a completed C1 lateral mass with C2 pedicle screw (Goel's technique) construct.

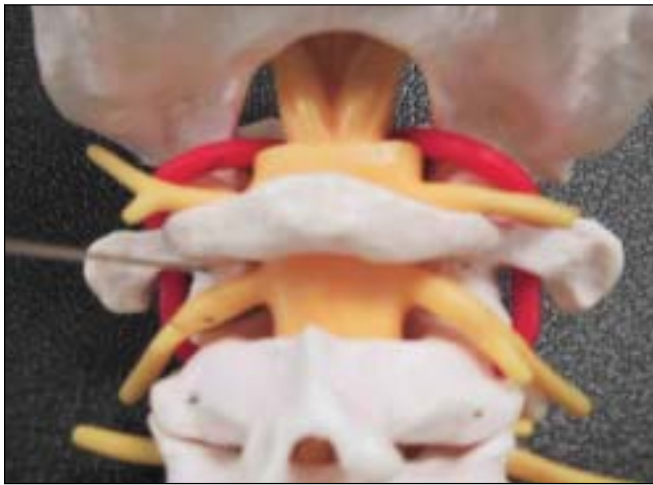

Figure 7: Photograph of a spine model demonstrating the entry point for a C1 lateral mass screw

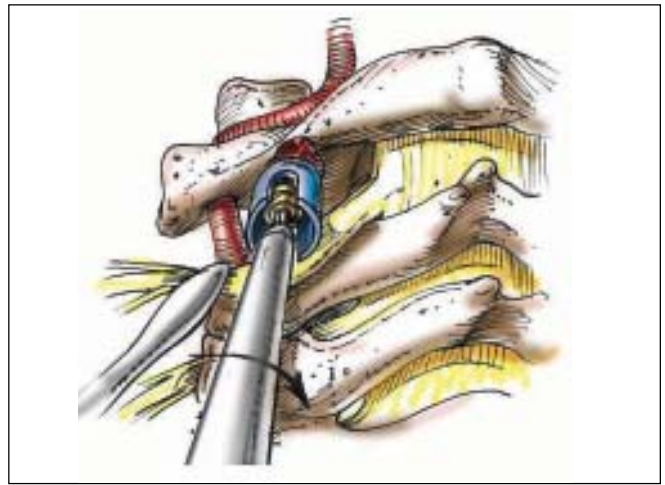


Figure 9: Artist's illustration of the placement of a C1 lateral mass screw

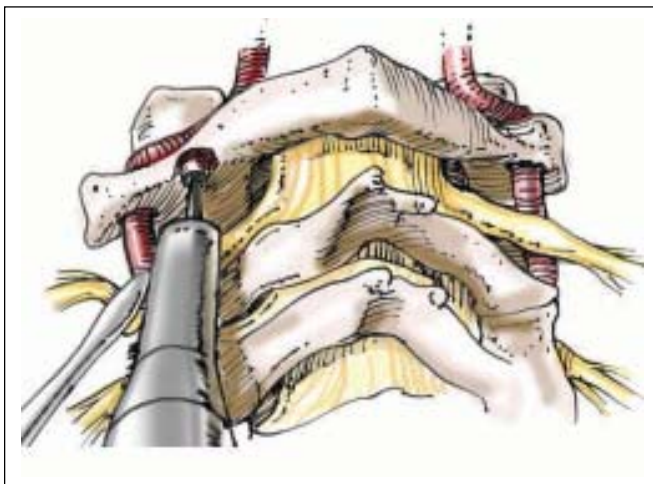


Figure 8: Artist's illustration of the creation of a defect in the posterior lamina of C1 prior to placement of a C1 lateral mass screw. This defect accommodates the screw shaft and head

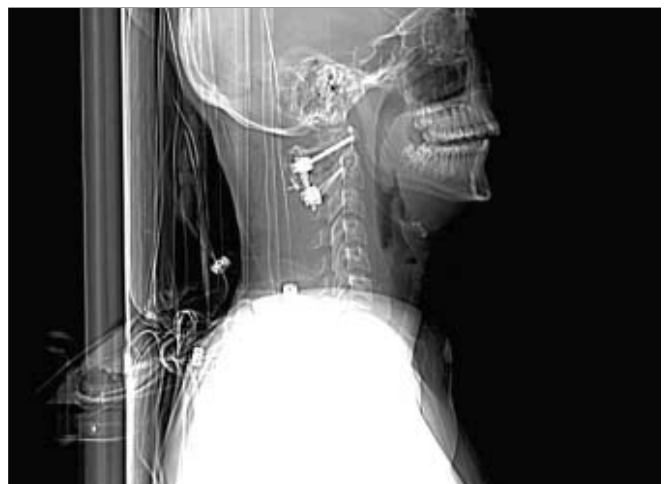

Figure 10: Lateral X-ray of a C1 lateral mass screw and C2 pars screw construct demonstrating the angulation and ideal positioning of the screws. An interspinous wiring has also been added to enhance the fusion

C1 lateral mass screw is placed (Figure 8).

We then turn our attention to placing a screw at C2. The C2 screw can either be placed in the pars of C2 or in the pedicle of C2. The pars of C2 is defined as the portion of the C2 vertebra between the superior and inferior articular surfaces. A C2 pars screw is placed in a trajectory similar to that of a C1-C2 transarticular screw except that it is much shorter. The entry point for the C2 pars screws 3 mm rostral and 3mm lateral to the inferior medial aspect of the inferior articular surface of C2. The screw follows a steep trajectory paralleling the C2 pars (Often 40 degrees or more) (Figure 9). We are usually able to achieve this trajectory through an incision that extends down to C4 without using a percutaneous stab incision at T1 (Figures 10 and 11). The screws are passed with 10 degrees of medial angulation. Screw length is typically 16 mm, which often stops short of the transverse foramen (Again, we confirm this with pre-operative CT scanning). Vertebral artery injury is still a risk with C2 pars screws but the risk is not as high

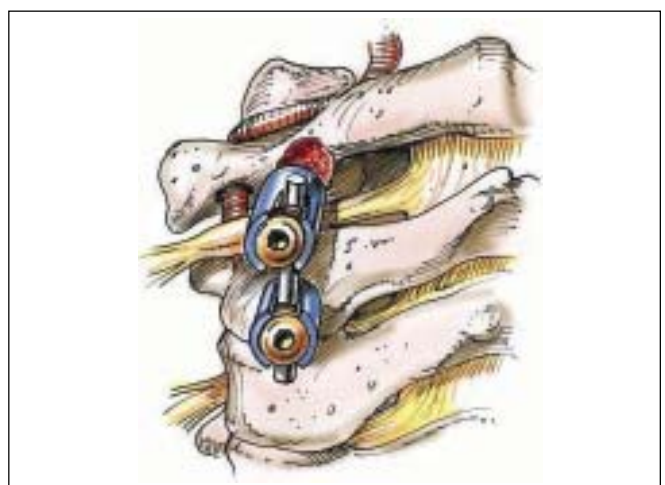


Figure 11: Artist's illustration of a completed C1 lateral mass with C2 pars screw construct

as with transarticular screws.

The C2 pedicle, on the other hand, is the portion of the C2 vertebrae connecting the dorsal elements with the vertebral body (The C2 pedicle is anterior to the C2 pars). The trajectory of the C2 pedicle screw is different than that of C2 pars screw. The entry point for a C2 pedicle screw is in the pars of C2, lateral to the superior margin of the C2 lamina. This point is usually 2 mm superior and 2 mm medial to the entry point for the C2 pars screw that we have just described. Goel's C1 lateral mass screw with C2 pars/ pedicle screw fixation (Figure 6). The screw is placed with 15-25 degrees of medial angulation. The thick medial wall of the C2 pedicle will help redirect the screw if necessary and prevent medial wall break out and entry into the spinal canal. The screw is placed after a drill is used to create the entry hole and after the hole is tapped. The trajectory of the C2 pedicle screw is 20 degrees up angle and 15-25 degrees medial from the entry point. The screws are tightened over a plate or rods are top loaded onto the screw heads (our modification).

The versatility of this technique for the treatment of various craniovertebral disorders has been highlighted by Goel et al in their numerous publications.^[31-35]

Recently, various authors have reported variations of this technique by substituting C1 or C2 laminar hooks or by using C2 translaminar screws.^[36]

Anterior C1 and C2 fixation technique

Transoral instrumentation for unstable craniovertebral junction was described by Goel et al in 1994.^[36] Harms and colleagues have recently used transoral technique to fixate the anterior cervical spine in patients undergoing transoral approaches to the odontoid for rotatory dislocations, tumors, or infections. The advantage of this technique is that the patient undergoing transoral decompression with anterior fusion can avoid a subsequent posterior neck incision for C1-2 fixation.

The technique is performed with the use of a "T-plate" (Depuy Spine, Raynham, MA). The horizontal portion of the plate is placed over the C1 lateral masses anteriorly and screws are placed through the plate apertures into the anterior C1 lateral mass to achieve a bicortical purchase. The vertical portion of the plate rests on the body of C2 inferior to the base of the dens. Two vertebral body screws are then placed just superior and parallel to the C2-3 disc space. This procedure requires an extensive posterior pharyngeal "C" shaped flap via the transoral approach. Midline linear posterior pharyngeal exposures are not recommended if this "T-plate" is used because they are prone to wound breakdown due to the profile of the "T-plate" causing pressure on the pharyngeal incision.

Discussion

We have utilized most of the constructs that we have described in the article in our practice over the past decade. In our opinion, C1-2 transarticular screws are the gold standard for re-establishing

C1-C2 stability. C1-2 transarticular screws, combined with a Sonntag type interlaminar wiring construct, have been shown to be biomechanically superior to all other constructs in achieving rigid fixation of the axis to the atlas. The C1 lateral mass screw technique, on the other hand, is very close to achieving the rigid fixation of the transarticular screw technique. The C1 lateral mass screw with C2 pars/ pedicle screw technique is advantageous because it is not constrained by vertebral artery anomaly or by lack of alignment of C1 on C2.

Either of these screw techniques allow the patient to avoid the use of a halo postoperatively. We typically utilize only a hard cervical collar after these procedures.

C1-2 posterior wiring and clamping techniques are not as rigid as the screw techniques. They do offer higher rates of fusion when combined with halo immobilization. However, they require an intact posterior arch of C1 and C2, which is not always available.

Anterior C1 and C2 fixation is technically possible but is challenging and risks retropharyngeal wound breakdown. This technique has limited applications.

References

- Mixter SJ, Osgood RB Traumatic Lesions of the Atlas and Axis. *Ann Surg* 1910;51:193-207.
- Gallie WE Fractures and Dislocations of Cervical Spine. *Amj Surg* 1939;46:495-499.
- Brooks AL, Jenkins EB. Atlantoaxial Arthrodesis by the Wedge Compression Method. *J Bone Joint Surg Am* 1978;60A: 279-84.
- Dickman CA, Sonntag VK, Papadopoulos SM, Hadley MN. The Interior Spinous Method of Posterior Atlantoaxial Arthrodesis. *J Neurosurg* 1991;74:190-198.
- Holness RO, Huestis WS, Howes WJ, Langille RA. Posterior Stabilization with an Interlaminar Clamp in Cervical Injuries: Technical Note and Review of the Long Term Experience with the method. *Neurosurg* 1984;14:318-322.
- Goel A, Laheri V. Plate and screw fixation for atlanto-axial subluxation. *Acta Neurochir (Wien)* 994; 129:47-53.
- Goel A, Desai K, Mazumdar D. Atlantoaxial fixation using plate and screw method: a report of 160 treated patients. *Neurosurg* 2002; 51:1351-1356.
- Harms J, Melcher P. Posterior C1-C2 Fusion with Polyaxial Screw and Rod Fixation. *Spine* 2001; 26(22):2467-2471.
- Subach BR, Morone MA, Haid RW Jr, McLaughlin MR, Rodts GR, Comey CH. Management of acute odontoid fractures with single-screw anterior fixation. *Neurosurg* 1999;45(4):812-9.
- Hinec VC, Hopkins CE. Measurement of the Atlanto-Dental Interval in the Adult. *AM Roent Radium Ther Nuc* 1960; 84:945-951.
- Meijers KA, Van Beusekom JT, Luyendijk W, Duijffjes F. Dislocation of the Cervical Spine with cord Compression Rheumatoid Arthritis. *J Bone Joint Surg* 1974; 56B:668-80.
- Fielding JW, Coehran G, Van B, Lawsing JF III, Hall M. Tears of the Transverse Ligament of the Atlas: A Clinical and Biomechanical Study. *J Bone Joint Surg AM for American* 1974; 56A:1683-1691.
- Jeanmeret B, Magerl F. Primary Posterior Fusions C1-2 in Odontoid Fractures: Indications, Technique, and Results of Transarticular Screw Fixation. *J Spinal Disord* 1992; 5:464-475.
- Wright NM, Lauryssen C. Techniques of Posterior C1-C2 Stabilization. *Tech in Neurosurg* 1998; 4:286-297,1998.
- Post AF, Narayan P, Haid RW Jr. Occipital neuralgia secondary to hypermobile posterior arch of atlas. Case report. *J Neurosurg* 2001; 94(2 Suppl):276-8.
- Hajek PD, Lipka K, Harline P, et al. Biomechanical study of C1-C2 posterior arthrodesis techniques. *Spine* 1993; 18: 173-177.
- Gallie WE. Fractures and Dislocation of the Cervical Spine. *AM J Surg* 1939; 46:495-499.
- Coyne TJ, Fehlings MG, Wallace MC, Bernstein M, Tator CH. C1-C2 Posterior Cervical Fusion: Long Term Evaluation of Results and Efficacy. *Neurosurg* 1995; 37:688-693.
- Smith MD, Phillips WA, Hensinger RN. Complications of Fusion to the Upper Cervical Spine. *Spine* 1991; 16:702-705.
- Grob D, Crisera JJ III, Panjabi MM, Wang P, Dvorak J. Biomechanical Evaluation of Four Different Posterior Atlantoaxial Fixation Techniques. *Spine* 1992; 17: 480-



- 490.
21. Haid RW. C1-C2 Transarticular Screw Fixation: Technical Aspects. *Neurosurg* 2001; 49:71-74.
 22. Haid RW, Subach BR, McLaughlin MR, Rodts GE, Wahlig JB. C1-C2 Transarticular Screw Fixation for Atlantoaxial Instability: A Six-Year Experience. *Neurosurg* 2001; 49:65-70.
 23. Madawi A, Casey A, Solanki G, et al. Radiological and anatomic evaluation of the atlantoaxial transarticular screw fixation technique. *J Neurosurg* 1997; 86:961-968.
 24. Paramore CG, Dickman CA, Sonntag VK. The anatomical suitability of the C1-2 complex for transarticular screw fixation. *J Neurosurg* 1996; 85: 221-224.
 25. Wright NM, Laurysen C. Vertebral artery injury in C1-2 transarticular screw fixation: results of a survey of the AANS/CNS section on disorders of the spine and peripheral nerves. *J Neurosurg* 1998; 88: 634-640.
 26. Fiore AJ, Haid RW, Rodts GE, Subach BR, Mummaneni PV, Rieel CJ, Birch BD. Atlantal lateral mass screws for posterior spinal reconstruction. *Neurosurg Focus* 12: 1-6. 2002.
 27. Fiore AJ, Mummaneni PV, Haid RW, Rodts GE, Sasso RC. C1 Lateral Mass Screws—Surgical Nuances. *Tech in Orthop* 17:1-6, 2002.
 28. Hott JS, Lynch JJ, Chamberlain RH, et al. Biomechanical comparison of C1-2 posterior fixation techniques. *J Neurosurg Spine*. 2005; 2: 175-81.
 29. Gupta S, Goel A. Quantitative anatomy of the lateral masses of the atlas and axis vertebrae. *Neurol India* 2000;48:120-5.
 30. Goel A, Pareikh S, Sharma P. Atlantoaxial joint distraction for treatment of basilar invagination secondary to rheumatoid arthritis. *Neurol India* 2005;53:238-40.
 31. Goel A, Kulkarni AG, Sharma P. Reduction of fixed atlantoaxial dislocation in 24 cases: technical note. *J Neurosurg Spine* 2005;2:505-9.
 32. Goel A, Phalke U, Cacciola F, Muzumdar D. Atlantoaxial instability and retroodontoid mass—two case reports. *Neurol Med Chir (Tokyo)*. 2004 ; 44:603-6.
 33. Goel A, Kulkarni AG. Mobile and reducible atlantoaxial dislocation in presence of occipitalized atlas: report on treatment of eight cases by direct lateral mass plate and screw fixation. *Spine*. 2004 15;29:E520-3.
 34. Goel A. Treatment of basilar invagination by atlantoaxial joint distraction and direct lateral mass fixation. *J Neurosurg Spine* 2004;1:281-6.
 35. Goel A, Karapurkar AP. Transoral plate and screw fixation of the craniovertebral region—a preliminary report. *Br J Neurosurg* 1994;8:743-5.
 36. Wright NM: Posterior C2 fixation using bilateral, crossing C2 laminar screws: case series and technical note. *J Spinal Disord Tech* 2004;17:158-62.

